

# Influence of Serous Retinal Detachment on the Outcome of Ranibizumab Treatment in Macular Edema Due to Branch Retinal Vein Occlusion in Short Term

## Retina Ven Dal Tıkanıklığına Bağlı Makula Ödeminin Tedavisinde Seröz Makula Dekolmanının Ranibizumab Tedavisi Sonucuna Kısa Dönemde Etkisi

Yeşim ERÇALIK<sup>1</sup>, Serhat İMAMOĞLU<sup>1</sup>, Handan BARDAK<sup>1</sup>, Esra TÜRKSEVEN KUMRAL<sup>1</sup>,  
Nursal Melda YENEREL<sup>2</sup>, Yavuz BARDAK<sup>3</sup>

### ABSTRACT

**Purpose:** To evaluate the influence of serous retinal detachment (SRD) on the outcome of intravitreal ranibizumab (IVR) injection in macular edema due to branch retinal vein occlusion (BRVO).

**Material and Methods:** Eighteen eyes with cystoid macular edema (CME) and SRD (study group) and 18 eyes with only CME (control group) that received PRN IVR injections during 6 months were evaluated retrospectively. Outcome measures were changes in central macular thickness (CMT) and best corrected visual acuity (BCVA), injection numbers and the the ellipsoid zone (EZ) status.

**Results:** Mean initial CMT in the study and control groups were 521±119 µm and 462±98 µm, respectively. Mean BCVA in the study and control groups were 0.93±0.46 and 0.73 ±0.53 LogMAR, respectively. The baseline CMT and BCVA weren't significantly different between the groups. The mean injection number was 2.88±0.83 in the study and 1.88±0.96 in the control group during the 6 months (p=0.003). At the last visit, the mean decrease in CMT and the improvement in BCVA wasn't significantly different between the groups.

**Conclusion:** The presence of SRD doesn't seem to effect the IVR therapy in BRVO negatively, concerning the change in CMT and BCVA. Eyes with SRD received more IVR injections compared to eyes with only CME. When whole patients were evaluated disruption of the ellipsoid zone rate was equal in both groups and was correlated with poorer BCVA and increased injection number .

**Key Words:** Ranibizumab, serous retinal detachment, vein occlusion.

### ÖZ

**Amaç:** Seröz retina dekolmanının (SRD) ven dal tıkanıklığına (VDT) bağlı makula ödeminin intravitreal ranibizumab (İVR) ile tedavisine etkisine değerlendirmek

**Gereç ve Yöntem:** Altı ay içinde PRN İVR enjeksiyonları ile tedavi edilen kistoid makula ödemli (KMÖ) ve SRD'li 18 göz (çalışma grubu) ve yalnızca KMÖ'lü 18 göz (kontrol grubu) retrospektif olarak değerlendirildi. Santral makula kalınlığı (SMK) ve en iyi düzeltilmiş görme keskinliğindeki (EİDGK) değişiklikler ile enjeksiyon sayıları ve elipsoid zonun (EZ) durumu incelendi.

**Bulgular:** Ortalama başlangıç SMK çalışma ve kontrol gruplarında sırasıyla 521±119 µm ve 462±98 µm olarak bulundu. Ortalama EİDGK çalışma ve kontrol gruplarında sırasıyla 0.93±0.46 ve 0.73 ±0.53 LogMAR idi. Başlangıç SMK ve EİDGK açısından gruplar arasında anlamlı bir fark yoktu. Son kontrolde SMK'da ortalama azalma ve EİDGK'da ortalama artış açısından gruplar arasında anlamlı değişiklik bulunmadı.

**Sonuç:** Seröz retina dekolmanının varlığının VDT'de İVR tedavisini SMK'daki ve EİDGK'daki değişiklikler açısından olumsuz etkilemediği görülmüştür. Yalnızca KMÖ'lü olgulara kıyasla SRD'li gözlerle daha sık enjeksiyon yapılmıştır. Tüm hastalar incelendiğinde elipsoid zondaki bozukluk oranı her iki grupta eşit ve azalmış EİDGK ve artmış enjeksiyon sayısı ile ilişkili bulunmuştur.

**Anahtar sözcükler:** Ranibizumab, seröz retina dekolmanı, ven tıkanıklığı.

1- Uz. Dr., Haydarpaşa Numune Eğt. ve Arş. Hastanesi, Göz, İstanbul, Türkiye  
2- Doç. Dr., Haydarpaşa Numune Eğt. ve Arş. Hastanesi, Göz, İstanbul, Türkiye  
3- Prof. Dr., Haydarpaşa Numune Eğt. ve Arş. Hastanesi, Göz, İstanbul, Türkiye

Geliş Tarihi - Received: 16.06.2017

Kabul Tarihi - Accepted: 05.08.2017

Ret-Vit 2018; 27: 117-121

Yazışma Adresi / Correspondence Address:

Yeşim ERÇALIK

Haydarpaşa Numune Eğt. ve Arş. Hastanesi, Göz, İstanbul, Türkiye

Phone: +90 212 271 5154

E-mail: yercalik@yahoo.com

## INTRODUCTION

Branch retinal vein occlusion (BRVO) is a common retinal vascular disease that often results in macular edema (ME), which is the most frequent cause of visual impairment in these patients.<sup>1</sup>

Optical coherence tomography (OCT) has provided qualitative analysis of retinal layers. Recent OCT studies have identified 3 morphological patterns in BRVO; cystoid macular edema (CME), serous retinal detachment (SRD), and a combined type of CME with SRD.<sup>2,3</sup>

Serous macular detachment (SRD) can occur in various chorioretinal diseases and has been reported in 15%-80.8% of the patients with BRVO.<sup>3-5</sup> Although SRD is a common pattern on OCT images, there is a lack of precise data regarding the influence of SRD on the response to therapies in BRVO patients. Therefore, the aim of this study is to evaluate the impact of SRD on the outcome of the intravitreal ranibizumab (IVR) treatment in BRVO patients.

## MATERIAL AND METHODS

This retrospective study included 36 eyes of 36 patients with cystoid macular edema (CME) due to BRVO, who received IVR injections at our hospital, between 2014 and 2016. Informed consents were obtained from all patients. The study followed the tenets of the Declaration of Helsinki. The outcome measures were; changes in the central macular thickness (CMT) and the best corrected visual acuity (BCVA), the number of the injections and the ellipsoid zone (EZ) status.

All patients underwent a complete eye examination, including BCVA measurement using Snellen's chart, biomicroscopy, fundoscopy, intraocular pressure (IOP) measurement by Goldmann applanation tonometer and spectral-domain optical coherence tomography examination (OCT) (RTVue-100; Optovue Inc, Fremont, CA). Serous retinal detachment was defined as a shallow elevation with an optical clear space between the retina and RPE. The CMT was defined as the sum of SRD height and neuroretinal thickness. We defined a well-delineated and continuous EZ within 1 mm of the foveal center as intact; otherwise, the EZ was considered to be disrupted. The pre-treatment status of the EZ in the OCT images of our patients was sometimes difficult to evaluate because CME reduced the signal intensity of the outer retina layers, therefore we decided to evaluate the post-treatment EZ status.

Inclusion criteria were CME with or without SRD due to BRVO and CMT greater than 300  $\mu\text{m}$ . Exclusion criteria were; uncontrolled glaucoma, vitreomacular interface abnormalities, prior vitrectomy, loss of vision as a result of other causes, diabetic retinopathy, intravitreal injection of anti-vascular endothelial growth factor (anti-VEGF) or steroid and laser treatment within the previous 3 months.

All injections were conducted under sterile conditions in the operating room. 0.5 mg IVR injection (Lucentis; Novartis Pharma AG, Basel, Switzerland, and Genentech, Inc., South San Francisco, CA) was conducted at the superotemporal pars plana. All patients were followed up for at least 6 months.

Statistical analyses were performed using the SPSS software version 16 for Windows. (SPSS Inc., Chicago, IL, USA) The variables were investigated using visual (histograms, probability plots) and the analytical methods (Kolmogorov-Smirnov/ Shapiro-Wilk's test) to determine whether or not they are normally distributed. Since the BCVA and CMT were not normally distributed; nonparametric tests were conducted to compare these parameters. Friedman tests were conducted to test whether there is a significant change in BCVA and CMT. Serial comparisons of pre- and post-treatment outcomes were performed with the Wilcoxon matched pairs nonparametric test. The Mann-Whitney U test was used to compare variables between the groups. The Chi-square test or Fisher's exact test (when chi-square test assumptions do not hold due to low expected cell counts), where appropriate, was used to compare these proportions in different groups. Best corrected visual acuities were converted to the logarithm of minimal angle of resolution (LogMAR) format for statistical manipulation. A p value of less than 0.05 was considered to show a statistically significant result.

## RESULTS

The patients were divided into two groups according to the OCT findings; the study group consisted of 18 eyes with CME and SRD and the control group of 18 eyes with only CME. All the patients received pro re nata (PRN) IVR injections after the first IVR injection, with monthly monitoring during the 6-month follow-up. Re-injection criteria were; CMT > 300  $\mu\text{m}$ , persistent SRD and a decrease in BCVA  $\geq 1$  Snellen line from the last visit. None of the patients received laser treatment during the 6 months.

There wasn't a significant difference between the groups concerning number of the eyes, age, gender, status of the lens, location of BRVO (superior or inferior) and previous laser. The characteristics of both groups are summarized in Table 1.

In the study group mean initial CMT was 521 $\pm$ 119  $\mu\text{m}$ . Macular thickness was significantly reduced after 6 months (289 $\pm$ 108  $\mu\text{m}$ , p=0.000). Changes in CMT after treatment in both groups are shown in Figure 1. Serous retinal detachment was resolved completely in all eyes. In the study group, the mean BCVA improved from 0.93 $\pm$ 0.46 LogMAR at baseline to 0.46 $\pm$ 0.30 LogMAR (p=0.001) at 6 months. Visual acuity changes in median LogMAR scores after treatment of both groups are shown in Figure 2 a and b.

Table I. Baseline characteristics			
	Study	Control	P value
Age (mean±sd)	62.9± 9.2	59.2±11.7	NS
Gender (F/M)	11/7	7/11	NS
Lens status (P/PS)	17/1	17/1	NS
Location of occlusion (S/I)	14/4	11/7	NS
Previous Laser (+)	5/13	4/14	NS
Baseline CMT (µm)	521± 119	462± 98	NS
Baseline BCVA (logMAR) (mean±sd)	0.93±0.46	0.73±0.53	NS

BCVA = best-corrected visual acuity; CMT = central macular thickness; P=phakia; PS=pseudophakia;S=superior;I=inferior; logMAR= logarithm of the minimum angle of resolution

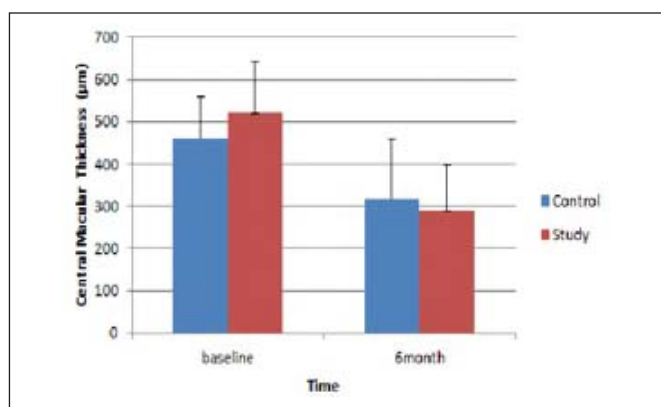


Figure 1. Changes in central macular thickness with time in study and control groups. The error bars denote the standard error of the mean (SEM).

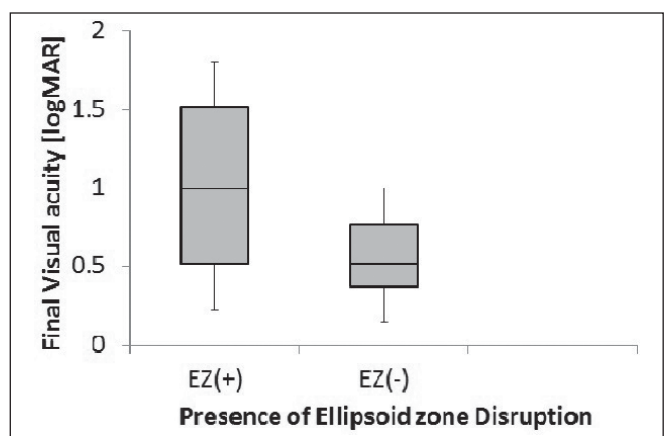


Fig 3. Boxplot graph shows the final best corrected visual acuity (LogMAR) in patients with or without Ellipsoid Zone (EZ) disruption.

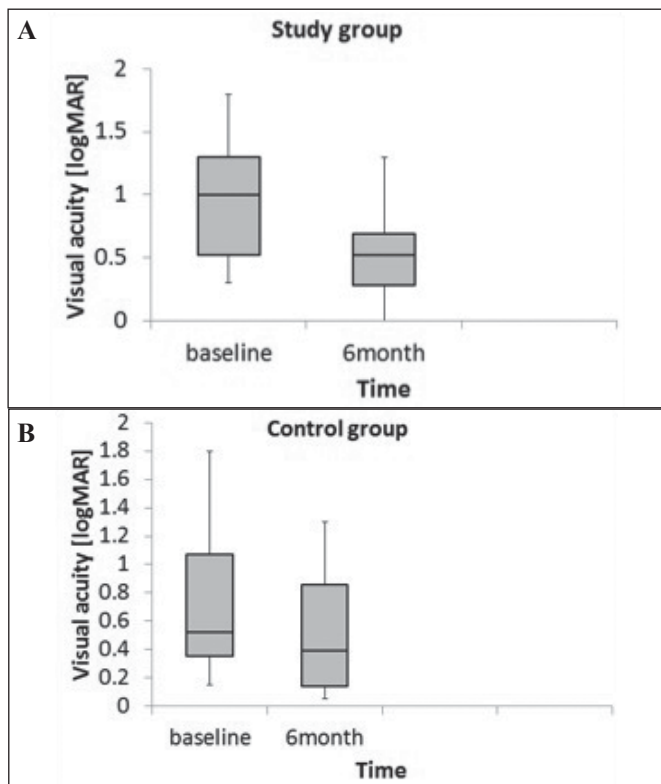


Figure 2. Boxplot graphs show the changes in best corrected visual acuity (LogMAR) with time in study (2a) and control (2b) groups.

In the control group, the mean CMT was 462±98 µm and the mean BCVA was 0.73±0.53 LogMAR. After 6 months CMT was significantly reduced (317±141µm, p=0.003) and improvement in BCVA was achieved (0.51±0.44 LogMAR, p=0.005).

The mean baseline CMT and the mean BCVA wasn't significantly different between the groups (p=0.14 and p=0.13, respectively). At the 6-month follow-up, the mean decrease in CMT and the improvement in BCVA wasn't statistically significant between the groups (p=0.27 and p=0.06, respectively). The mean injection number was 2.88±0.83 in the study and 1.88±0.96 in the control group during the 6 months, the difference was statistically significant (p=0.003).

When whole patients were evaluated; the ellipsoid zone integrity at the 6-month visit was disrupted in 61.1% of the eyes both in the study and control groups, the difference wasn't statistically significant (p=1.0). Baseline and final low visual acuities were significantly correlated with the post-treatment EZ disruption in the treated eyes (p=0.016 and p=0.000 respectively). Correlation between the EZ disruption and the final BCVA is shown in Figure 3. In eyes

with increased injection number ( $n > 2$ ) EZ disruption rate was 81.2% ( $p = 0.041$ ).

Significant cataract progression or vision-threatening complications were not encountered in any eye. There wasn't any significant IOP change.

## DISCUSSION

The pathogenesis of SRD has not yet been well established. The mechanism is thought to be the leakage from the retinal or choroidal circulation into the subretinal space, exceeding the compensatory draining capacity.<sup>6</sup> In SRD, fluid accumulates between the neurosensory retina and the RPE, seen as hyporeflective spaces on OCT.<sup>2</sup>

Intravitreal injection of ranibizumab has been reported to be effective in reducing ME associated with BRVO.<sup>7</sup> However, the issue of whether the presence of SRD effects the treatment outcomes after anti-VEGF treatment in BRVO patients with ME, has not been precisely addressed. The influence of SRD on visual acuity (VA) and CMT in BRVO is unclear and different study results were reported. Poon et al. reported a significantly thicker CMT in patients with SRD than in those without it. In their study, the amount of reduction in CMT was greater and the improvement of VA was better in the SRD group after 6 months. These results suggested that the presence of SRD observed on OCT may be an indicator of favorable clinical response to intravitreal bevacizumab injections.<sup>8</sup> Gallego-Pinazo et al. found a poorer BCVA and greater CMT at baseline in patients with SRD. At the final visit, BCVA differed significantly in their patients. Their results suggested that the presence of SMD in patients with BRVO is related to a worse visual outcome.<sup>9</sup> Hoeh et al. reported no significant difference in VA at baseline and last visit and the final CMT between patients with or without SRD. In their study, presence of SRD didn't influence functional and morphological response to bevacizumab treatment.<sup>10</sup> In Kang's study, there was a modest correlation between SRD and final VA, but it was not clinically significant.<sup>11</sup> In our study, there wasn't any significant difference in the initial and final CMT between the groups. Our baseline and final BCVA did not differ significantly between patients with or without SRD, corroborating Hoeh's study.<sup>10</sup> In our opinion, presence of SRD in BRVO doesn't seem to effect the IVR therapy in BRVO patients negatively. Noma et al. used microperimetry to show that SRD itself does not influence macular sensitivity, and that SRD does not necessarily lead to a poor visual prognosis in BRVO patients.<sup>12</sup>

Inflammatory factors may be strongly associated with the occurrence of SRD in BRVO patients. VEGF is an important angiogenic factor that causes an increase in vascular permeability and is increased in the hypoxic retina.<sup>13</sup> Noma et

al. reported that vitreous levels of VEGF and other potent vasopermeability factors were higher in BRVO patients with SRD compared to those with CME, and suggested that this elevated inflammatory factors could play a role in the formation of SRD.<sup>12</sup> In our study, eyes with SRD received significantly more IVR injections compared to eyes with only CME. Our increased injection number in the study group might be related to the increased vasopermeability factors in SRD patients as mentioned in Noma's study.<sup>12</sup> Other studies found no difference in the injection numbers between the eyes with or without SRD. Poon et al. reported no difference in the number of bevacizumab injections between the group with SRD ( $2.36 \pm 1.29$ ) and the group without SRD ( $2.13 \pm 0.84$ ) after 6 months, although they had greater CMT in the SRD group.<sup>8</sup> Gallego-Pinazo et al. also found similar IVR injection numbers in both groups;  $5.0 \pm 2.98$  injections in 12.5 months in the SRD group and  $4.3 \pm 2.55$  injections in 10.4 months in control group.<sup>9</sup>

The photoreceptor layer death due to ischemia or inflammation can lead to the disruption of IS/OS in eyes with BRVO.<sup>14</sup> Murakami et al. reported that the integrity of the foveal photoreceptor layer is a visual prognostic factor in BRVO.<sup>15</sup> Histologic studies have shown that severe ME can effect the photoreceptor layer in the fovea, which then results in photoreceptor dysfunction.<sup>16</sup> In our study, the rate of EZ disruption didn't differ between the groups, this might be due to the similar CMT between the groups. Ellipsoid zone disruption was in correlation with decreased initial and final BCVA and the increased injection number. Our results are consistent with those of Shin et al. They found that the integrity of the foveal photoreceptor is significantly correlated with VA at baseline and the final visit in patients with ME due to BRVO.<sup>14</sup>

The limitations of the present study were its retrospective nature, small sample size, lack of quantitative measurement of the EZ and lack of angiographic findings. Although the ischemia might also effect visual prognosis negatively, it is often difficult to analyze it because of retinal hemorrhage.<sup>17</sup> Final CMT and BCVA and the EZ status did not differ significantly between patients with or without SRD in our study group. In our opinion, presence of SRD in BRVO doesn't seem to negatively effect the IVR therapy on functional outcome in BRVO patients. Further prospective studies with a larger sample size are needed to clarify the role of SRD in BRVO and its effects on prognosis and treatment outcomes.

## Disclosures

**Financial support:** None.

## Conflict of Interest Statement:

The authors declare no conflict of interest.

## REFERENCES / KAYNAKLAR

1. Rehak J, Rehak M. Branch retinal vein occlusion: pathogenesis, visual prognosis, and treatment modalities. *Curr Eye Res* 2008;33:111–131.
2. Spaide RF, Lee JK, Klancnik JK Jr, et al. Optical coherence tomography of branch retinal vein occlusion. *Retina* 2003;23:343–347.
3. Shroff D, Mehta DK, Arora R, et al. Natural history of macular status in recent-onset branch retinal vein occlusion: an optical coherence tomography study. *Int Ophthalmol* 2008;28:261–268.
4. Yamaguchi Y, Otani T, Kishi S. Serous macular detachment in branch retinal vein occlusion. *Retina* 2006;26:1029–1033.
5. Tsujikawa A, Sakamoto A, Ota M, et al. Serous retinal detachment associated with retinal vein occlusion. *Am J Ophthalmol* 2010;149:291–301.
6. Battaglia Parodi M, Isola V. Branch retinal vein occlusion and exudative retinal detachment: pathogenetical aspects. *Ophthalmologica* 1994;208:29–31.
7. Campochiaro PA, Heier JS, Feiner L, et al; BRAVO Investigators. Ranibizumab for macular edema following branch retinal vein occlusion: six-month primary end point results of a phase III study. *Ophthalmology* 2010;117:1102–1112.
8. Poon YC, Chen CH, Kuo HK, et al. Clinical implications of serous retinal detachment in branch retinal vein occlusion and response after primary intravitreal bevacizumab injection. *J Ocul Pharmacol Ther* 2013;29:319–324.
9. Gallego-Pinazo R, Dolz-Marco R, Pardo-López D, et al. Ranibizumab for serous macular detachment in branch retinal vein occlusions. *Graefes Arch Clin Exp Ophthalmol* 2013;251:9–14.
10. Hoeh AE, Ruppenstine M, Ach T, et al. OCT patterns of macular edema and response to bevacizumab therapy in retinal vein occlusion. *Graefes Arch Clin Exp Ophthalmol* 2010;248:1567–1572.
11. Kang HM, Chung EJ, Kim YM, et al. Spectral-domain optical coherence tomography (SD-OCT) patterns and response to intravitreal bevacizumab therapy in macular edema associated with branch retinal vein occlusion. *Graefes Arch Clin Exp Ophthalmol* 2013;251:501–508.
12. Noma H, Funatsu H, Mimura T, et al. Vitreous inflammatory factors and serous macular detachment in branch retinal vein occlusion. *Retina* 2012;32:86–91.
13. Kaur C, Foulds WS, Ling EA. Blood-retinal barrier in hypoxic ischaemic conditions: Basic concepts, clinical features and management. *Prog. Retin. Eye Res* 2008;27:622–647.
14. Shin HJ, Chung H, Kim HC. Association between integrity of foveal photoreceptor layer and visual outcome in retinal vein occlusion. *Acta Ophthalmol* 2011;89:35–40.
15. Murakami T, Tsujikawa A, Ohta M, et al. Photoreceptor status after resolved macular edema in branch retinal vein occlusion treated with tissue plasminogen activator. *Am J Ophthalmol* 2007;143:171–173.
16. Tso MO. Pathology of cystoid macular edema. *Ophthalmology* 1982;89:902–915.
17. Wolf-Schnurrbusch UE, Ghanem R, Rothenbuehler SP, et al. Predictors of short-term visual outcome after anti-VEGF therapy of macular edema due to central retinal vein occlusion. *Invest Ophthalmol Vis Sci* 2011;52:3334–3337.